



***Octopus vulgaris* (Cephalopoda: Octopodidae) Gametogenesis:  
A Histological Approach  
to the Verification of the Macroscopic Maturity Scales**

INÉS GONÇALVES, JOÃO SENDÃO, J. & TERESA C. BORGES\*)

6 Text-Figures and 6 Tables

Portugal  
Algarve  
Gametogenesis  
Maturity Scales  
Histology

**Contents**

|   |    |
|---|----|
| Zusammenfassung .....   | 79 |
| Abstract .....  | 79 |
| 1. Introduction .....   | 80 |
| 2. Material and Methods .....   | 80 |
| 3. Results .....  | 81 |
| 3.1. Stages of Oogenesis .....  | 81 |
| 3.2. Stages of Spermatogenesis .....  | 83 |
| 3.3. Histological Stage of Development and Macrostage of Maturity .....                 | 84 |
| 3.3.1. Oocyte Diameter Distribution .....   | 84 |
| 3.3.2. Morphology Classification of Histological Stage and Macrostage of Maturity ..... | 84 |
| 4. Discussion .....   | 85 |
| Acknowledgements .....  | 87 |
| References .....  | 87 |

**Die Gametogenese bei *Octopus vulgaris* (Cephalopoda: Octopodidae):  
Verifizierung der makroskopischen Maturitätsskala  
durch histologische Methoden**

**Zusammenfassung**

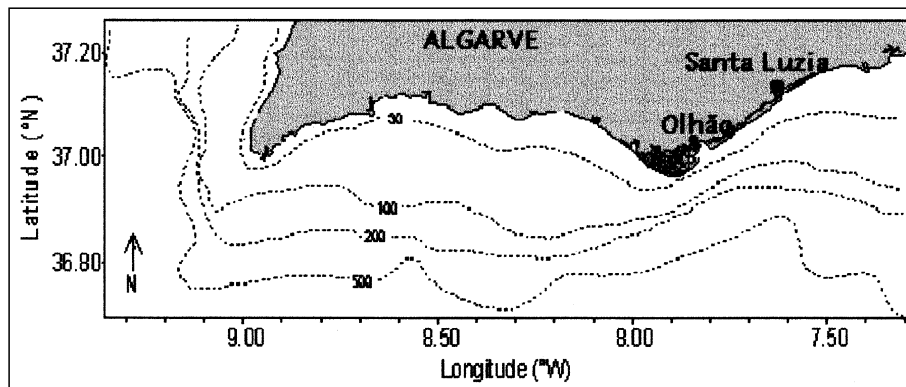
Für das Verstehen der Reproduktionsbiologie und die Beziehung zwischen dem abbleichenden Bestand und dessen Regeneration ist die Kenntnis des Maturationsprozesses von zentraler Bedeutung. Für die Gonaden der Cephalopoden gibt es verschiedene Maturitätsskalen. Eine richtige und in großem Maßstab anwendbare Skala wäre beim Studium der Lebenszyklen der Cephalopoden von großem Wert. Das Anliegen der vorliegenden Studie war es, die makroskopische Maturitätsskala für *Octopus vulgaris* anhand histologischer Methoden zu bestätigen. Die Veränderungen an Hoden und Ovarien während der geschlechtlichen Reifung erlaubten die Abgrenzung von sechs verschiedenen histologischen Stadien der Spermatogenese und sieben Stadien der Oogenese. Die relative Häufigkeit der Stadien wurde bei jeder Kategorie berechnet. Durch den Vergleich der Häufigkeit mit den makromorphologischen Veränderungen wäre es möglich, der Entwicklung der einzelnen Zyklen der Gonaden zu folgen. Die Studie lieferte auch den Nachweis, dass *Octopus vulgaris* periodisch abbleicht.

**Abstract**

Knowledge of the maturation process is vital to understanding reproductive biology and the relationship between spawning stock and recruitment. There are various gonad maturity scales for cephalopods. A correct and widely applicable scale would be of great value for studying cephalopod life cycles. The purpose of the present study was to validate, using histological methods, the macroscopic maturity scale used for *Octopus vulgaris*. The changes in testes and ovaries during sexual maturation permitted the determination of six different histological stages for spermatogenesis and seven for oogenesis. The relative frequencies of these stages in each of the categories of the maturity scale, were calculated. By comparing these frequencies along with the macro-morphological changes, it was possible to follow closely the single cycle development of the gonads. The study also provided evidence suggesting that *Octopus vulgaris* is an intermittent spawner.

\*) Authors' address: INÉS GONÇALVES, JOÃO SENDÃO, J. & TERESA C. BORGES, Center of Marine Science (CCMAR), University of Algarve, Campus Gambelas, 8000 Faro, Portugal.

Text-Fig. 1.  
Map of the southern coast of Portugal,  
showing the two areas of study.



## 1. Introduction

Maturity scales are frequently used in population analyses in fisheries biology. Maturation and age and size at maturity are a basic information in the study of reproductive cycles and management models (JUANICÓ, 1983).

Various scales have been developed for cephalopod maturity stage determination. Criteria for dividing the process of sexual development into maturity scale usually involve complex sexual characters. There are scales based on measurements, counts, weights, morphological descriptions and histology (GONÇALVES, 1993). The simplest classifications considered only two stages, immature and mature, according to the presence or absence of spermatophores in males and mature oocytes in females. Between these two extremes intermediate stages "in maturation" may also be considered. A spent stage is also identifiable, in both males and females, in which most of the gametes have already been emitted.

There have been various attempts to develop a single, macroscopic maturation scale. ARKHIPKIN (1992) developed a maturation scale for both males and females, applicable to all groups of cephalopods. JUANICÓ (1983) compiled and compared several maturation scales for squid. According to SAUER & LIPINSKI (1990), the development of a reliable maturity scale should involve the establishment of a precise and logical correspondence between the changes occurring in the gonads (reflecting the development of the gametes during maturation, observed by microscopic investigation) and their gross morphology. Macroscopic analysis alone may lead to grave errors in the interpretation of the processes occur-

ring inside the gonads, processes often decisive for the definition of fecundity indices and spawning periods.

Gametogenesis in cephalopods has been investigated by many authors, including ARNOLD and WILLIAMS-ARNOLD (1977), WELLS & WELLS (1977), KNIPE & BEEMAN (1978) for *Loligo opalescens*, BOYLE & KNOBLOCH (1983) for *Eledone cirrhosa*, SAUER & LIPINSKI (1990) for *Loligo vulgaris reynaudii*, COELHO (1990) for *Illex illecebrosus*, LOPES (1995) for *Loligo vulgaris*, TAKAHASHI & YAHATA (1973) for *Todarodes pacificus*, RICHARD (1971) for *Sepia officinalis*.

This paper describes a histological study of gametogenesis in *Octopus vulgaris*. The objective was to identify and characterise the histological stages and to develop a microscopic maturity scale, and relate it to the macroscopic maturity scales frequently used.

## 2. Material and Methods

The specimens of *Octopus vulgaris* were collected from trawl and artisanal fisheries in two fishing harbours of the Algarve Coast: Santa Luzia and Olhão (Text-Fig. 1).

All animals sampled were measured (dorsal mantle length, DML, cm), weighed (total body weight, TW, g) and their maturity stages were determined according to information given in GUERRA (1975), MANGOLD, (1963), GONÇALVES (1993), ARANCIBIA & TRAN-

COSO (1984) and NIGMATULLIN cited by DIA (1988). Six maturity stages were considered for females and five for males (Tables I, II). For histological examination, 2 or 3 gonads at each stage of maturity and mantle length class (Table III), were obtained by dissection of fresh animals. No spent stage was found. Since the samples collected were provided by commercial fisheries, the probability of having small individuals was scarce, and only one immature male was found. The gonads were immediately fixed in San Felice's solution. After 12-24 hours of fixation, they were stored in 70 % ethanol. The tissues were then dehydrated through an alcohol series and embedded in Paraplast. Sections were cut at 5-7 microns and stained with

Table 1.  
Maturity stages for *Octopus vulgaris* females.

| Stage | Designation             | Observation   |
|-------|-------------------------|---|
| I     | Immature                | White, small, homogeneous ovary and oviduct glands. Slender and semitransparent oviducts.   |
| II    | Beginning of maturation | Medium-sized, white and heterogeneous ovary. Small oviduct glands and a white denticulate band in anterior region. White oviducts are relatively thick.   |
| III   | Maturing                | Ovary characterised by its increased volume, heterogeneous aspect and yellowish-white colour. Medium-sized oviduct glands with well defined white denticulate band and the appearance of a pink band. White, thick oviducts.  |
| IV    | Mature                  | Large, yellowish ovary occupying approximately 1/3 of the mantle. Well developed oviduct glands with large denticulate band and the second band brown, occupying almost half of the gland. White, thick oviducts.   |
| V     | Spawning                | Maximum-size, yellowish ovary, where some free eggs can be observed. Maximum-size oviduct glands with three distinct regions: white denticulate anterior region, brown medium region and a third, posterior region, white with longitudinal "buds". White, very thick oviducts. |
| VI    | Spent                   | Small, heterogeneous ovary without eggs. Oviduct glands are smaller, heterogeneous, with distinct regions and a relatively dark colour. Yellowish-White and thick oviducts.   |

Masson's Trichrome and Hematoxylin-eosin to identify the cell development stages present in the ovaries and testes. For each cell type, sizes were measured at the maximum diameter.

Oocytes were grouped into 100 µm classes. Modal components of each size frequency distribution were identified by the Bhattacharya method (BHATTACHARYA, 1967).

In an attempt to validate the macroscopic maturity scale, the variation of the frequency of the histological stages in each macrostage was studied and the  $\chi^2$  test was used to determine the significance level between two successive macrostages.

### 3. Results

#### 3.1. Stages of Oogenesis

In the ovaries of *O. vulgaris* the developing oocytes are attached by a peduncle to the strings of gonadal tissue suspended from the roof of the ovary. The oogonia appear attached to the germinal epithelium and the process of maturation starts when the transformation of oogonia into the first oocyte type begins.

During oogenesis the oocyte becomes progressively more elongated, with a subsequent narrow elongation of the apical zone forming the oocyte peduncle. Finally the oocytes turn smooth (chorion becomes the outer surface when the follicular cells disappear) and free, finally reaching the oviducts.

The number of cell types and the cell size range both increase as the gonad matures.

The histological observation of ovaries in different maturation macrostages, allowed the distinction of seven different histological stages for oogenesis, based on the morphology of oocytes and follicles.

##### Stage 1

The oogonies (Text-Fig. 2a) are small round cells of 6 to 12 µm diameter and without visible cytoplasm. These cells are attached to the germinal epithelium.

##### Stage 2

An oocyte at this stage measures from 15 to 50 µm, with a nucleus size/cell size ratio of 40 % to 83 %. At this stage oocytes show aggregated chromatin in the nucleus. In the earliest stages they are similar to the oogonia, with a thin layer of cytoplasm surrounding the nucleus; this layer becomes thicker as the growth process continues (Text-Fig. 2b).

##### Stage 3

At this stage oocytes are associated with one or several follicle cells and each contains various spherical nucleoli in the nucleus. Follicle cells have an oval shape, are smaller than the oocytes and are located on the connective tissue (Text-Fig. 2c and d). At this stage oocytes range from 18 to 156 µm, with a nucleus size/cell size ratio of 19 % to 83 %.

Table 2.  
Maturity stages for *Octopus vulgaris* males.

| Stage | Designation   | Observation   |
|-------|---------------|---|
| I     | Immature      | Needham sac without spermatophores. Small, transparent testis and gonoduct.   |
| II    | In maturation | A few spermatophores in Needham sac may be present, almost all of them are empty. Thin and white vas deferens.                                    |
| III   | Mature        | Needham sac with spermatophores. Homogeneous and white testis. Yellowish-White and thick vas deferens.  |
| IV    | Spawning      | Needham sac full of spermatophores (more than 100). Testis colour and aspect advanced near to exhaustion. Yellowish-White and thick vas deferens. |
| V     | Spent         | Only few spermatophores in Needham sac. Small and atrophied testis with relatively dark colour. Yellowish-White vas deferens.                     |

Table 3.  
Number of *Octopus vulgaris* sampled and the range of dorsal mantle length (DML).

| FEMALES |                  |                | MALES |                  |                |
|---------|------------------|----------------|-------|------------------|----------------|
| STAGE   | TOTAL OF SAMPLES | DML RANGE (cm) | STAGE | TOTAL OF SAMPLES | DML RANGE (cm) |
| I       | 28               | 9.8 – 16.2     | I     | 1                | 5.1            |
| II      | 20               | 10.4 – 17.7    | II    | 18               | 7 – 14         |
| III     | 19               | 12.6 – 17.3    | III   | 38               | 10.8 – 23.5    |
| IV      | 15               | 12.6 – 19.5    | IV    | 22               | 12.8 – 25.2    |
| V       | 9                | 17.5 – 24.5    |       |                  |                |

##### Stage 4

The oocyte is surrounded by a layer of flat follicle cells. This is the beginning of the previtellogenic phase. The oocyte diameter varies between 29 and 653 µm. The portion of the cell occupied by the cytoplasm is larger than that occupied by the nucleus (the nucleus size/cell size ratio ranged from 7 % to 63 %). The follicle cells change shape to become cuboidal in the terminal phase of this stage. In the terminal phase two layers of follicular cells are observed, the inner consisting of cuboidal cells, the outer of flat follicular cells. At this stage the cells have one distinct spherical nucleolus in the nucleus (Text-Fig. 2e and f).

##### Stage 5

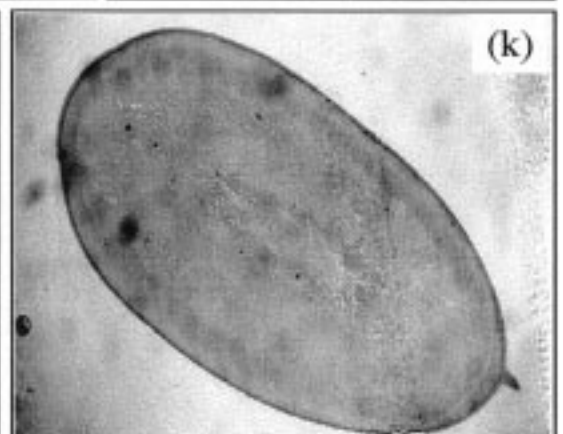
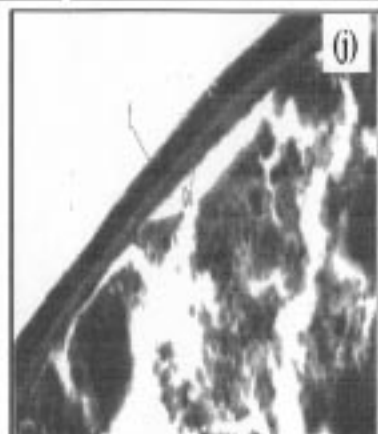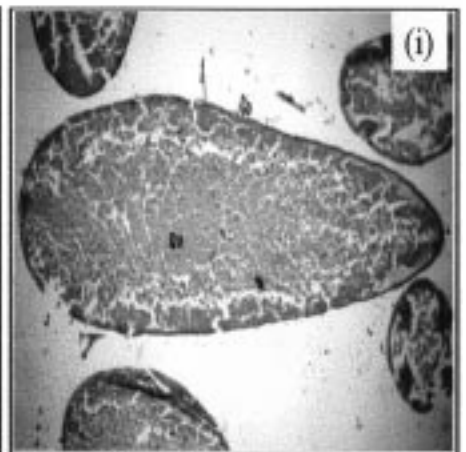
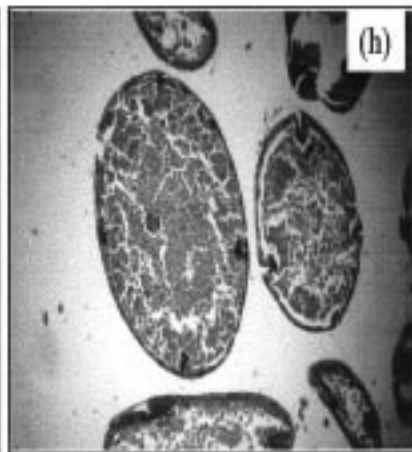
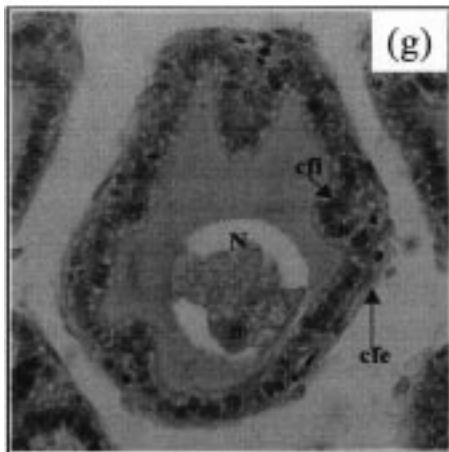
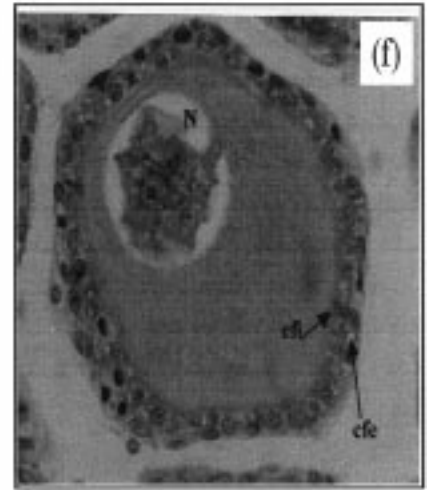
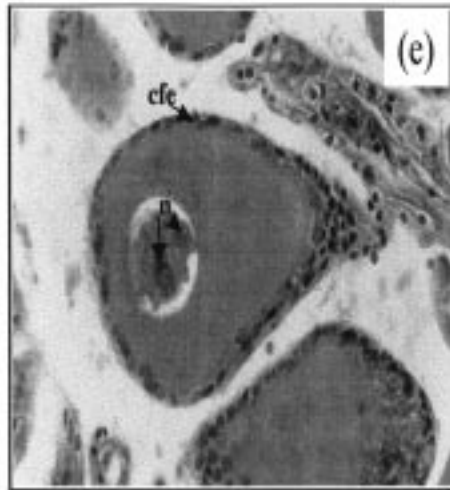
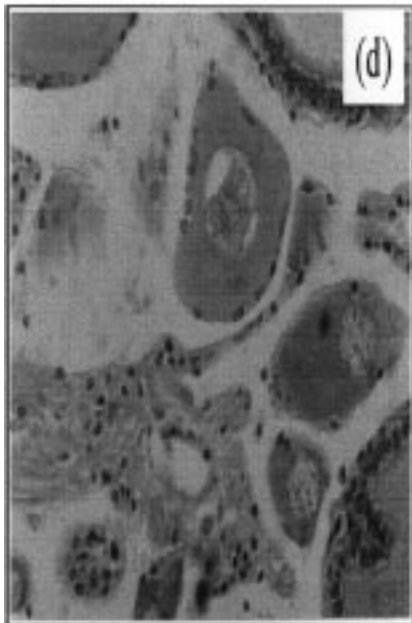
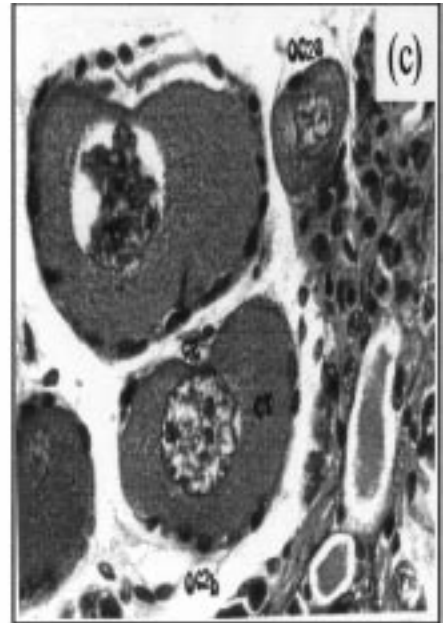
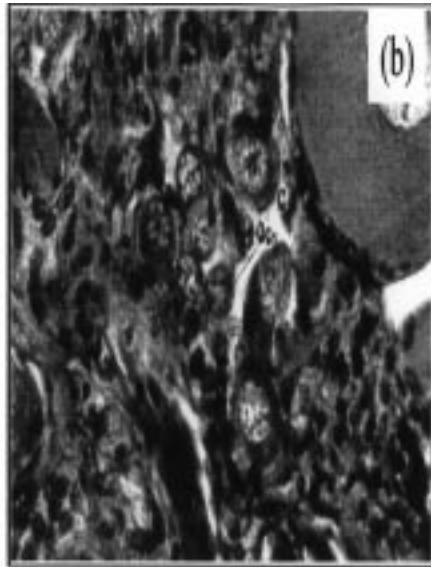
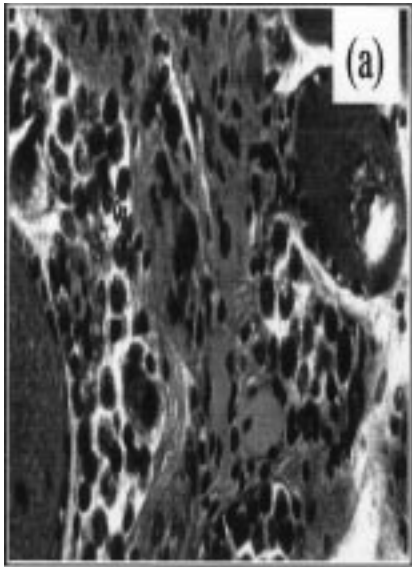
The follicle epithelium initiates the oocyte embedding by intensive multiplication of the follicle cells, with a subsequent displacement of the nucleus to the polar zone of the cell (Text-Fig. 2g). Oocyte size increases to a maximum diameter of 129 to 760 µm, with a nucleus size/cell size ratio of 7 % to 50 %. There is an initiation of nucleoli degeneration and the first production of yolk globules.

##### Stage 6

This stage is characterised by very strong oocyte diameter increase. The follicular epithelium is active in vitellogenesis and the formation of a chorion. The follicular folds are being displaced towards the periphery of the oocyte by the formation of yolk. Oocyte sizes range between 132 and 3270 µm (with peduncle). The affinity of yolk granules for green, the follicle for pink and the chorion for red allows a clear differentiation after staining with Masson's Trichrome (Text-Fig. 2h).

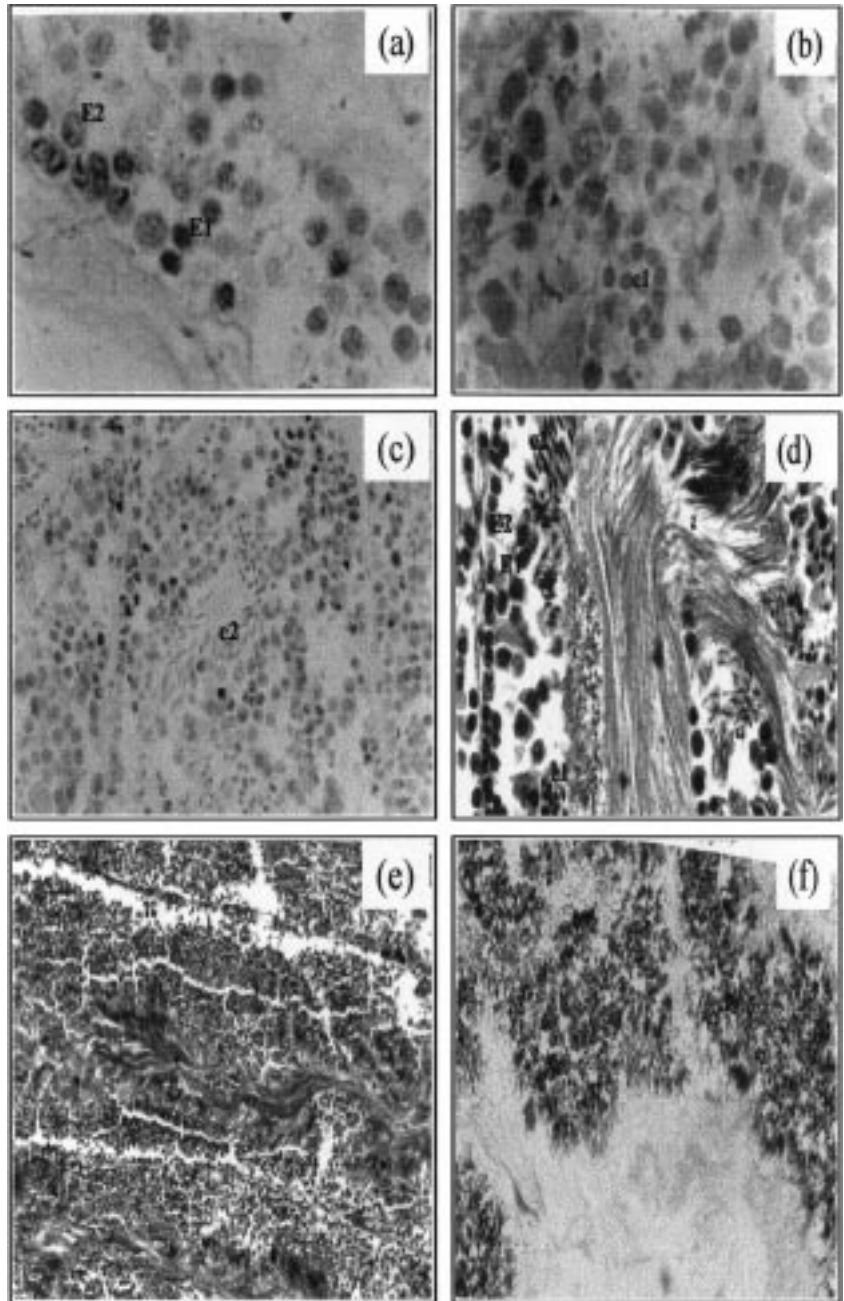
##### Stage 7

The cytoplasm is completely filled with yolk granules, the whole being surrounded by a chorion (Text-Fig. 2i, j, k). The follicular layer becomes thin and finally degenerates, leaving a mature oocyte which is ready for ovulation. The sizes of oocytes vary between 1860 and 2410 µm.



Text-Fig. 2 (opposite page). ◀◀◀  
 Histological stages observed during ovary development.

- a) First stage, oogonia (Og).  
 Cf = Follicular cells.  
 × 1000.
- b) Oocytes in histological stage 2 (Oc).  
 N = nucleus; CT = cytoplasm.  
 × 1000.
- c,d) Oocytes in histological stage 3 showing various nucleoli and surrounded by one (Oc2a) and by few (Oc2b) follicular cells.  
 N = nucleus; CT = cytoplasm; CR = chromosomes.  
 × 400.
- e,f) Oocytes in histological stage 4. Single-layer of flat follicle cells surrounding the oocyte (e) and with a layer of cuboidal follicle cells (f).  
 Cfi = cuboidal follicle cells; Cfe = flat follicle cells; N = nucleus; CT = cytoplasm; n: nucleolus.  
 × 400.
- g) Oocyte in histological stage 5, follicular epithelium penetrating the oocyte.  
 Cfi = cuboidal follicle cells; Cfe = flat follicle cells; N = nucleus; CT = cytoplasm; n: single nucleolus.  
 × 400.
- h) Oocyte in histological stage 6, regression of follicular folds.  
 Gv = yolk granules.  
 × 400.
- i,j,k) Oocytes in histological stage 7.  
 i) At the end of vitellogenesis.  
 Gv = yolk granules; Co = chorion; f = follicle.  
 × 40.  
 j) Showing abundant yolk (Gv) and a thick chorion (Co).  
 f = follicle.  
 × 1000.  
 k) Mature oocyte.  
 × 40.



Text-Fig. 3.  
 Histological stages observed during testis development.

- a) Histological stage 1 (× 1000), showing primary spermatocytes (E1) and secondary spermatocytes (E2).
- b) Histological stage 2 (× 1000), differentiation of primary round spermatidia (e1).
- c) Histological stage 3 (× 100), the primary spermatidia give rise to the secondary spermatidia (e2).
- d) Histological stage 4, formation of first spermatozoa (× 400) E1: primary spermatocytes, E2: secondary spermatocytes, e1: primary spermatidia, e2: secondary spermatidia, eZ: transition between spermatidia and spermatozoa, Z: spermatozoa.
- e) Histological stage 5, spermata and spermatozoa in abundance (× 100).
- f) Histological stage 6, showing empty spaces (× 100), only few secondary spermatocytes, spermatidia and spermatozoa.

### 3.2. Stages of Spermatogenesis

Histologically, the testis in *Octopus vulgaris* consists of a complex of seminiferous tubules where spermatogenesis occurs. As in other cephalopods (ARNOLD & WILLIAMS-ARNOLD, 1977) spermatogenesis in *O. vulgaris* is characterised by the development of spermatogenic stages proceeding from the periphery to the centre. In each seminiferous tubule several developmental stages may be present simultaneously, forming a gradient, depending on the position in the tubule: those cells in more advanced stages being closer to the lumen of the tubule, and those in the initial stages of development being close to the periphery. In the testes examined six cell types were identified.

The spermatogonia are cells which undergo a limited number of mitotic divisions, and are situated next to the wall of the germinal epithelium. They form the primary spermatocytes. The spermatogonia and the primary spermatocytes are difficult to distinguish from each other, both being relatively large cells with a large, distinct nucleus. The first meiotic division occurs, and the primary spermatocytes become secondary spermatocytes. A second meiotic division occurs immediately afterwards, so the secondary spermatocytes become spermatidia. The transformation of the spermatidia to spermatozoa occurs by a process of differentiation known as spermiogenesis. Morphologically, this differentiation involves the formation of a tail, a flagellum (for cell mobility) and a change from a round to an elongate shape.

The spermatozoa are grouped around the lumen, with the flagella towards the centre. Finally it is possible to follow the increase in numbers of the spermatozoa in Needham's sac. The spermatogenesis was divided into

The spermatozoa are grouped around the lumen, with the flagella towards the centre. Finally it is possible to follow the increase in numbers of the spermatozoa in Needham's sac. The spermatogenesis was divided into

six histological stages, according to the different types of cells present, and the predominance of each type during the maturation process.

### Stage 1

In the first stage (Text-Fig. 3a) the seminiferous tubules are well defined but small. Spermatogonia (11–9  $\mu\text{m}$ ) are present in low numbers, along with primary (8.2–7  $\mu\text{m}$ ) and secondary spermatocytes (5.8–4.6  $\mu\text{m}$ ).

### Stage 2

In this stage round spermatidia (3.5–2.3  $\mu\text{m}$ ) start to differentiate. No spermatogonia can be seen, and the seminiferous tubules are slightly bigger (Text-Fig. 3b).

### Stage 3

The primary spermatidia give rise to the secondary spermatidia (2.4–5.8  $\mu\text{m}$ ). The central lumen can be distinguished at the centre of the seminiferous tubule, before the initiation of the production of the first spermatozoa (Text-Fig. 3c).

### Stage 4

The seminiferous tubules in this stage are clearly defined along the testis. Primary and secondary spermatocytes, primary and secondary spermatidia and few spermatozoa are present. The general structure of the tissue in this stage is shown in Text-Fig. 3d.

### Stage 5

This stage contains large and well defined tubules. The empty spaces between cells are greatly reduced. Spermatidia and spermatozoa (11.6–15.2  $\mu\text{m}$ ) are abundant in the central lumen. Movement of spermatozoa from the testis is indicated by the orientation of the tails (Text-Fig. 3e).

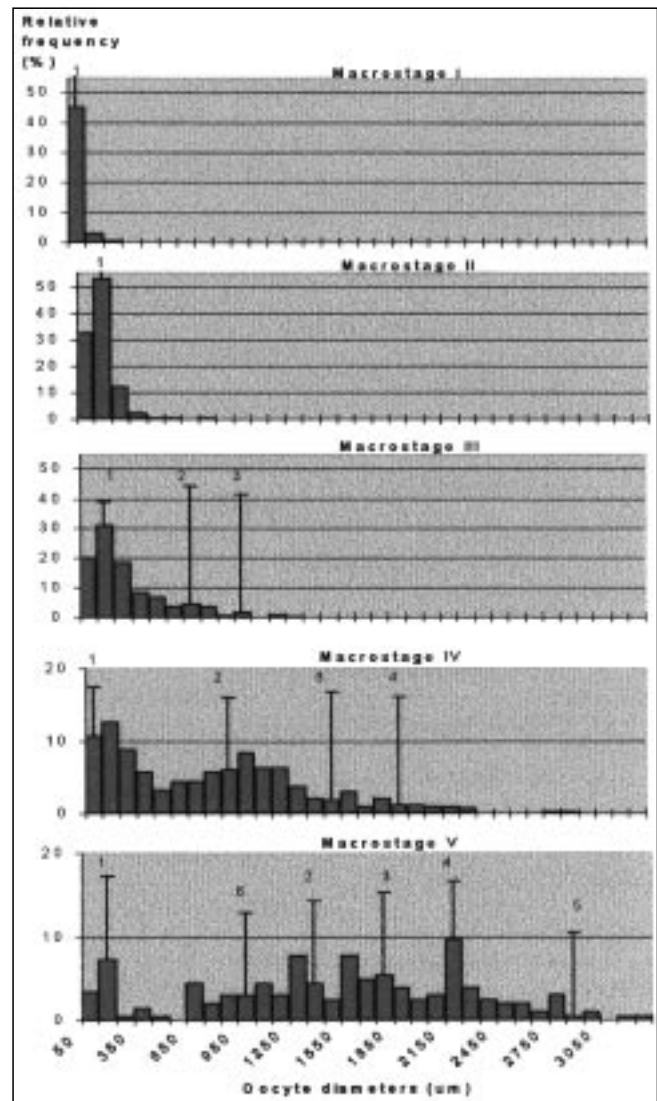
### Stage 6

At this stage empty spaces can be seen, indicating that spermatozoa have been expelled from the testis, stored in spermatophores which are passed to Needham's sack. Only few secondary spermatocytes, spermatidia and spermatozoa are observed, dispersed throughout the seminiferous tubules (Text-Fig. 3f).

## 3.3. Histological Stage of Development and Macrostage of Maturity

### 3.3.1. Oocyte Diameter Distribution

The oocyte size distribution for each maturity stage is shown in Text-Fig. 4. Analysis using the Bhattacharya method permits the determination of six modal components and their development through five macrostages. The results of this analysis are represented in an appendix and are summarised in Table IV. Comparing the modal components and oocyte diameters provides a view of the oocyte batch growth as a series of overlapping stages. The first modal component, with mean values between 95.36 and 153.28  $\mu\text{m}$  consisted of oocyte histological stages 1, 2, 3, and 4, and a few of histological stages 5 and 6. The second component, with mean values between 621.77 and 1305.91  $\mu\text{m}$  consisted of oocytes in stage 5 (advanced) and 6. The third component (966.97 to 1719.57  $\mu\text{m}$ ) consisted of oocytes in histological stage 6 only. The fourth component (1910.64 and 2163.3  $\mu\text{m}$ ) and the fifth component (2850  $\mu\text{m}$ ) consisted of oocytes in stage 6 (advanced) and stage 7. The sixth component with a value of only 900  $\mu\text{m}$  appears as a result of the development of oocytes to the most advanced classes.



Text-Fig. 4. Oocyte size distribution at each macrostage of maturity.

### 3.3.2. Morphology Classification of Histological Stage and Macrostage of Maturity

Text-Figs. 5 and 6 show the histological stage with relative frequency at each macrostage of maturity for females and males, respectively. In the immature and mature ovaries of *O. vulgaris* cells in various stages of oogenesis are present. The least developed ovaries show five histological stages, from oogonia to oocytes in the early yolk-formation stage. In both macrostages I and II there are abundant previtellogenic oocytes. Vitellogenic oocytes appear in macrostage II but are more abundant in more developed stages of maturity. In mature and spawning ovaries oocytes in histological stage 7 were observed while no oogonia and oocytes in stage 2 were found in macrostage V.

The comparison between macroscopic and microscopic development stages of maturity in males of *O. vulgaris* (Text-Fig. 6) shows that the same histological stage may also be observed in more than one macrostage. In immature testes not only spermatogonia but also spermatidia were observed. The advanced stages of maturity were characterised by a great abundance of spermatidia and spermatozoa. However, in maturity stage V empty spaces and a lower density of cellular stages in some seminiferous tubules were observed, leading to the conclu-

sion that many spermatozoa had been expelled, given for the large number of spermato-phores present in Needham's sac.

The results of the  $\chi^2$  test, comparing the successive macrostages, showed a clear difference between categories of macroscopic development based on microscopic analysis ( $p < 0.001$ ) (Table 5).

#### 4. Discussion

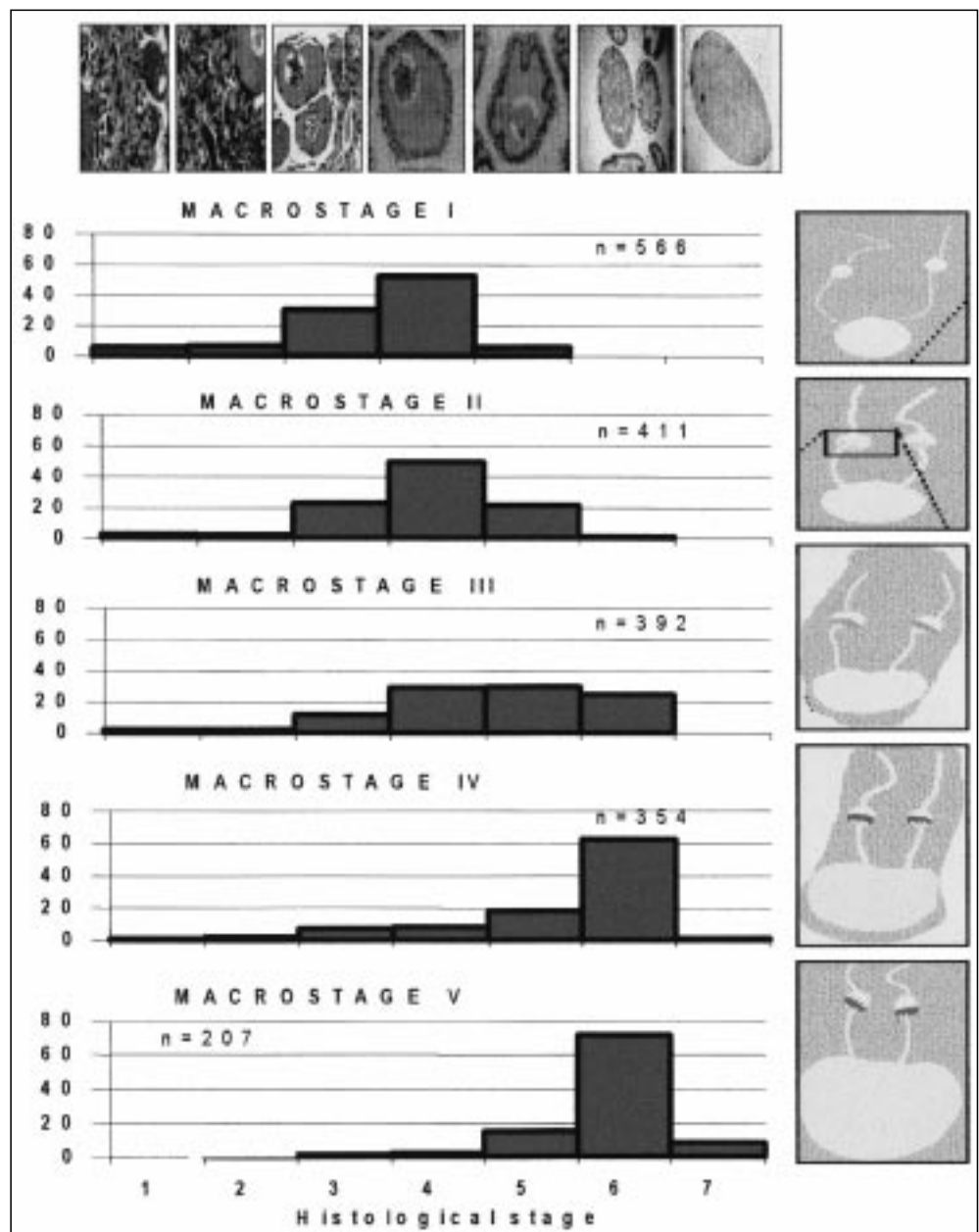
The process of oocyte maturation in *Octopus vulgaris* is similar to that in other cephalopods, as described in previous works. Table VI shows the stage numbers and measurements of oocytes observed by several authors during oogenesis, for different species of cephalopods. The number of discrete stages considered by each author to describe the maturation process appears to be dependent on the different criteria used, as was noted by JUANICO (1983).

The most important difference with respect to oogenesis among the different cephalopod groups appears to be in the timing of the decomposition of the nucleolus and the penetration of RNA into the cytoplasm of the oocyte (see ARKHIPKIN, 1992). In the present work it was possible to observe the nucleolus until the initiation of the formation of the first yolk granules.

A comparison of oogenesis and spermatogenesis illustrates that maturation occurs earlier in males than in females. The males became mature at a smaller size and probably a younger age than the females. The testis attains a relatively large size 2-3 months before the ovary begins to enlarge, while in the females, the ovary, the oviduct glands

Table 4. Resume of Bhattacharya method results, based on oocyte frequency distributions in each macrostage of maturity of *O. vulgaris* females.

| Stage | Modals Components | Average | Standard deviation (sd) | Population (n) | Separated index (s.i) |
|-------|-------------------|---------|-------------------------|----------------|-----------------------|
| I     | 1                 | 95.36   | 62.782                  | 562            | -----                 |
| II    | 1                 | 118.75  | 93.118                  | 408            | -----                 |
| III   | 1                 | 153.28  | 127.647                 | 305            | -----                 |
|       | 2                 | 621.77  | 143.777                 | 69.49          | 3.452                 |
|       | 3                 | 966.67  | 155.433                 | 9.33           | 2.305                 |
| IV    | 1                 | 133.10  | 138.214                 | 112            | -----                 |
|       | 2                 | 907.01  | 301.420                 | 129.29         | 3.521                 |
|       | 3                 | 1508.16 | 91.620                  | 14.82          | 3.059                 |
|       | 4                 | 1910.64 | 79.187                  | 10.73          | 2.972                 |
| V     | 1                 | 121.96  | 53.681                  | 23             | -----                 |
|       | 2                 | 900.00  | 157.045                 | 16             | 7.384                 |
|       | 3                 | 1305.91 | 103.207                 | 33.58          | 3.119                 |
|       | 4                 | 1719.57 | 187.266                 | 33.95          | 2.848                 |
|       | 5                 | 2163.23 | 72.779                  | 31.16          | 3.412                 |
|       | 6                 | 2850.00 | 351.163                 | 11             | 3.240                 |



Text-Fig. 5. Histological stage relative frequency at each macrostage of maturity in females of *Octopus vulgaris*.

and the oviducts enlarge greatly 3–4 months before spawning (MANGOLD, 1983). In *O. vulgaris* mating frequently occurs when the females are immature. The spermatozoa can be transferred to the immature females where spermatozoa are stored in the spermatheca of the oviducal gland. In *Illex argentinus* the earlier start of maturation in males also occurs but in this case both sexes conclude functional maturity simultaneously. This simultaneous maturation appears to correspond to the absence of seminal receptacles in *Illex*, which would otherwise permit precocious copulation and storage of sperm in immature females, until the initiation of spawning (ARKHIPKIN & LAPTIKHOVSKY, 1994). COELHO (1990) reports that in *Illex illecebrosus*, for the oocyte and spermatozoa to be mature at the same time, the mature spermatozoa must be stored longer in the males than the mature oocytes in the females, and that this might permit more than one period of spermatozoa transfer.

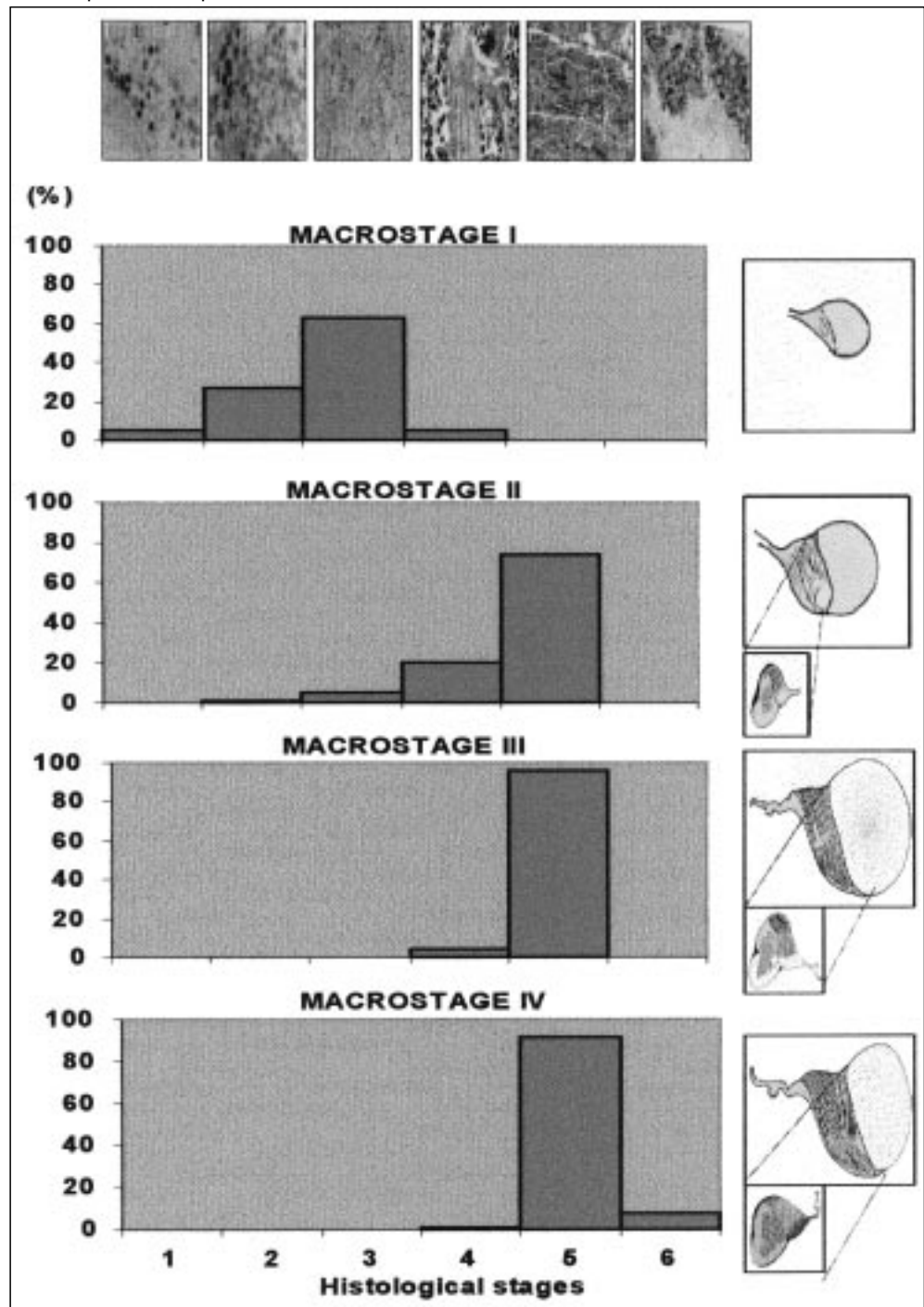
The development of tubules and spermatids seems to be much more rapid in *O. vulgaris* than in *Loligo vulgaris reynaudii* as described by SAUER & LIPINSKI (1990) and in *Illex illecebrosus* as described by COELHO (1990). The same appears to be true of the degeneration process. SAUER & LIPINSKI (1990) did not observe any degenerative process in males of *Loligo vulgaris reynaudii*. In the present work, the last histological stage observed in the males appeared to be a condition characteristic of senility, since cell diversity was diminished and large spaces were visible, indicating that large numbers of spermatozoa had been emitted. In the last stages of maturation the histological development stages appear to be similar to those described by GRIEB & BEEMAN (1978) for mature and maturing males of *Loligo opalescens*, while they seem to be different from those described by SCHULDT (1979) for *Illex argentinus*, in which primary gonial cells are still found in mature individuals. The histological study of *O. vulgaris* spermatogenesis and oogenesis

Table 5.  $\chi^2$  test results comparing successive macrostages of maturity, based on histological observation of ovary and testis of *O. vulgaris*.

| Comparing macrostage | $\chi^2$ | p      | Significance level |
|----------------------|----------|--------|--------------------|
| I e II               | 72.55    | <0.001 | very significant   |
| II e III             | 129.49   | <0.001 | very significant   |
| III e IV             | 126.85   | <0.001 | very significant   |
| IV e V               | 37.65    | <0.001 | very significant   |

| Comparing macrostage | $\chi^2$ | p      | Significance level |
|----------------------|----------|--------|--------------------|
| I e II               | 161.65   | <0.001 | very significant   |
| II e III             | 19.51    | <0.005 | very significant   |
| III e IV             | 9.88     | <0.005 | very significant   |



Text-Fig. 6. Histological stage relative frequency at each macrostage of maturity in males of *Octopus vulgaris*.



shows that animals in the later stages of maturation do not have germinal cells that would permit a second spawning.

The analyses of cell diameters illustrated that size ranges of successive stages overlap. Cell size appears to be a poor criterion for describing some of the stages of maturity. It is also evident from the frequency distribution analysis of the oocytes that each modal component is composed of more than one oocyte stage, and there is, therefore, no clear separation of oocytes at the same stage of development. The hypothesis that oocyte diameter varies with female size cannot be excluded, although this was not observed in this study.

The failure to observe the earliest cellular stages indicates a monocycle ovarian development. The filling of the ovary does not appear to be due to the oogonia or to the oocytes in the first stages of development, but rather to the progress of vitellogenesis in the oocytes already present, which undergo a considerable increase in size during this process. The oocytes are, as a consequence, developing in classes of increasing diameter, giving the appearance of modal component.

In contrast to the species studied here, VILLANUEVA (1992) reported a new reproductive strategy in cephalopods, the occurrence of continuous spawning in Cirrata octopus. These animals have a cyclic and continuous ovarian development, spawning several times throughout the life cycle, which is longer.

The oocyte frequency distribution relative to the macrostage of maturity shows that oocyte development is asynchronous. Oocytes of various stages of development are present in the ovaries permitting a continued production of ova once spawning is initiated (ROCHA et al., 1996). The asynchrony of oocyte growth could be related to an intermittent spawning pattern as defined for the genus *Illex* by LAPTIKHOVSKY & NIGMATULLIN (1993) and commented by ROCHA et al. (1996). In *O. vulgaris* it seems that the mature females expel oocytes intermittently, as the ovary becomes full, and without intermissions, in contrast to *Sepia officinalis* (BOLETZKY, 1987) where long pauses occur.

The different maturation stages described, defined on the basis of a collection of external morphological characteristics of the gonads, permit a rapid analysis of the physiological state of the gonads. This type of analysis (utilised in routine biological sampling programs) requires the support of a microscopic examination, to define, exactly, the development of gametogenesis. Only in this way is it possible to establish, with accuracy, the relationship between the maturation process and the morphological appearance of the gonad. In this attempt to verify the macroscopic maturity scale used for *O. vulgaris*, it was possible, using the  $\chi^2$  test on frequency variation of the histological stages, to demonstrate significant differences between all the macrostages. However the male data presented for macrostage I was based on the observation of a single specimen. The assessment of the variations of the histological stages in *Octopus vulgaris* is needed to characterise this stage.

#### Acknowledgements

We thank staff from Santa Luzia and Olhão selling markets for help with the sampling collection, specially Mr. OLIVEIRA. Dr. T. MODESTO and Dr. S. LOPES for advice on the sample techniques and suggestions which

Table 6. Ocitary stages (bold) and oocyte diameters (in parenthesis,  $\mu\text{m}$ ) of different species of cephalopods.

| This work               | KNIFE & BEEMAN (1978)    | LOPES (1995)           | BOTTKE (1974)               | COELHO (1990)             |
|-------------------------|--------------------------|------------------------|-----------------------------|---------------------------|
| <i>Octopus vulgaris</i> | <i>Loligo opalescens</i> | <i>Loligo vulgaris</i> | <i>Alloteuthis subulata</i> | <i>Illex illecebrosus</i> |
| <b>1</b><br>(6-12)      | <b>1a</b>                |                        |                             | <b>1a</b><br>(9-15)       |
| <b>2</b><br>(15-50)     | <b>1b</b>                |                        |                             | <b>1b</b><br>(15-30)      |
|                         | <b>1c</b>                |                        |                             | <b>2</b><br>(20-90)       |
| <b>3</b><br>(20-160)    | <b>2</b>                 | <b>1</b><br>(30-390)   | <b>1</b><br>(100)           | <b>3</b><br>(90-160)      |
| <b>4</b><br>(30-650)    | <b>3</b>                 | <b>2</b><br>(40-500)   | <b>2</b><br>(250-700)       | <b>4</b><br>(180-210)     |
| <b>5</b><br>(130-760)   | <b>4</b>                 | <b>3</b><br>(50-1100)  |                             | <b>5</b><br>(200-260)     |
| <b>6</b><br>(130-3270)  | <b>5</b>                 | <b>4</b><br>(320-1740) | <b>3</b><br>(to 1300)       | <b>6</b><br>(270-340)     |
|                         |                          | <b>5</b><br>(430-2370) |                             | <b>7</b><br>(320-500)     |
| <b>7</b><br>(1860-2410) | <b>6</b>                 | <b>6</b><br>(820-2190) |                             | <b>8</b><br>(400-700)     |

improved the study. Prof. Dr. K. ERZINI for the advice on statistical analysis and Prof. Dr. J. WALLACE for the English translation of the article. We are grateful to University colleagues for assistance, especially Dr. R. MACHAS. Part of this research was financed by one project under the auspices of the European Union (DG XIV, no 97/0086).

#### References

- ARANCIBIA, H. & TRONCOSO, G., 1984: Estudio de talla y peso de primera madurez sexual en el pulpo *Octopus vulgaris* CUVIER, 1797. – Informe Final SERNAP. Relatório de Proyecto de Investigación, 56 p.
- ARKHIPKIN, A.I., 1992: Reproductive system structure, Development and Function in Cephalopods with a New General Scale for Maturity Stages. – J. Northw. Atl. Fish. Sci., **12**, 63–74.
- ARKHIPKIN A. & LAPTIKHOVSKY, V., 1994: Seasonal and interannual variability in growth and maturation of winter-spawning *Illex argentinus* (Cephalopoda, Ommastrephidae) in the Southwest Atlantic. – Aquat. Living Resour., **7**, 221–232.
- ARNOLD, J.M. & WILLIAM, L.D., 1977: Cephalopoda: Decapoda. – In: GIESE A.C. & PEARSE J.S. (Eds.): Reproduction of Marine Invertebrates, Academic Press, New York, 243–290.
- BHATTACHARYA, C.G., 1967: A simple method of resolution of a distribution into gaussian components. – Biometrics, **23** (1), 115–135.
- BOLETZKY, S.V., 1987: Fecundity variation in relation to intermittent or chronic spawning in the cuttlefish, *Sepia officinalis* L. (Mollusca, Cephalopoda). – Bull. mar. Sci., **40**, 382–387.
- BOTTKE, W., 1974: The fine structure of ovarian follicle of *Alloteuthis subulata* LAM. (Mollusca, Cephalopoda). – Cell. Tiss. Res., **150**, 463–479.
- BOYLE, P.R. & KNOBLOCH, D., 1983: The female reproductive cycle of octopus *Eledone cirrhosa*. – J. Mar. Biol. Ass. U. K., **63**, 71–83.
- COELHO, M.L., 1990: Gametogenesis in the squid *Illex illecebrosus*. – Journal Cephalopod Biology, **1** (2), 75–99.
- DIA, M.A., 1988: Biologie et exploration du poulpe *Octopus vulgaris* (CUVIER, 1797) des Côtes Mauritanienues. – Thèse Présentée à L'Université de Bretagne Occidentale pour L'Obtention du Doctorat de 3<sup>ème</sup> Cycle. Spécialité de Oceanographie, Mention en Biologie, 165 p.

- GONÇALVES, J.M., 1993: *Octopus vulgaris* CUVIER, 1797 (polvo comum): Sinopse da biologia e exploração. – Trabalho de síntese a apresentar para as Provas de Aptidão Pedagógica e Capacidade Científica, para acesso à categoria de Assistente de Carreira Docente Universitária. Universidade dos Açores. Departamento de Oceanografia e Pescas, Açores, 469p.
- GRIEB, T.M. & BEEMAN, R.D., 1978: A study of spermatogenesis in the spawning population of the squid, *Loligo opalescens*. Calif. dept. – Fish & Game, Fish Bull., **169**, 11–21.
- GUERRA, A., 1975: Determinación de las fases del desarrollo sexual de *Octopus vulgaris* LAMARCK, mediante un índice de madurez. – Inv. Pesq. **39** (2), 397–416.
- JUANICO, M., 1983: Squid maturity scales for population analysis. – In: CADDY, J.F. (Ed.): Advances in assessment of world Cephalopod resources, FAO Fish. Tech. Pap., **231**, 341–348.
- KNIFE, J.H. & BEEMAN, R.D., 1978: Histological observations on the oogenesis in *Loligo opalescens*. – Calif. dept. Fish. & Game, Fish Bull., **169**, 23–33.
- LAPTIKHOVSKY, V. & NIGMATULLIN, C.M., 1993: Egg size, fecundity, and spawning in females of the genus *Illex* (Cephalopoda: Ommastrephidae). – ICES J. mar. Sci., **50**, 393–403.
- LOPES, S., 1995: Aspectos da gametogénese e da fecundidade da espécie *Loligo vulgaris* (LAMARCK, 1799). – Relatório de Estágio, Universidade do Algarve, Faro, 64 p.
- MANGOLD-WIRZ, K., 1963: Biologie des Cephalopodes benthiques et nectoniques de la Mer Catalane. – Vie et Milieu, **13** (suppl.), 1–285.
- MANGOLD, K., 1983b: *Octopus vulgaris*. – In: BOYLE, P.R. (Ed.): Cephalopod Life Cycles. Species accounts. Vol. I, Academic Press, London, 335–364.
- MANGOLD, K., 1987: Reproduction. – In: BOYLE, P.R. (Ed.): Cephalopod Life Cycles. Comparative reviews. Vol. II., Academic Press, London, 157–200.
- RICHARD, A., 1971: Contribution à l'étude expérimentale de la croissance et de la maturation sexuelle de *Sepia officinalis* L. (Mollusque Céphalopode). – Doctoral Dissertation (Thèse d'Etat), Univ. Lille (nr. 243), Lille, France, 264 pp.
- ROCHA, F., GONZÁLEZ, A.F., RASERO, M., GUERRA, A., CASTRO, B.G. & CORTEZ, T., 1996: An overview on the reproductive strategies in Cephalopoda. – ICES Working Group on Cephalopod Fisheries and Life History, 1–6.
- SCHULDT, M., 1979: Contribucion al conocimiento del ciclo reproductor de *Illex argentinus* (Cephalopoda: Ommastrephidae). – Monografias, **10**, Comission de Investigaciones Cientificas, Provincia de Buenos Aires, Argentina, 110 pp.
- SAUER, W.H. & LIPINSKI, M.R., 1990: Histological validation of the morphological stages of sexual maturity in Chokker squid *Loligo vulgaris reynaudii* D'ORB. (Cephalopoda: Loliginidae). – S. Afr. J. mar. Sci., **9**, 189–200.
- TAKAHASHI, N. & YAHATA, T., 1973: Histological Studies on the Maturation of the Ovary in the Squid, *Todarodes pacificus*. – Bull. of the Fac. of Fish., Hokkaido University, **24** (2), 63–68.
- VILLANUEVA, R., 1992: Continuous spawning in the cirrate octopods *Opisthoteuthis agassizii* and *O. vossi*: features of sexual maturation defining a reproductive strategy in cephalopods. – Mar. Biol., **114**, 265–275.
- WELLS, M.J. & WELLS, J., 1969: Pituitary analogue in the *Octopus*. – Nature, **222**, 293–294.
- WELLS, M.J. & WELLS, J., 1977: Cephalopoda: Octopoda. – In: GIESE, A.C. & PEARSE J.S. (Eds.): Reproduction of Marine Invertebrates. Vol. IV, Academic Press, New York, 291336.

Manuskript bei der Schriftleitung eingelangt am 2. April 2001